

Otterbein University

## Digital Commons @ Otterbein

---

Nursing Student Class Projects (Formerly MSN)

Student Research & Creative Work

---


Fall 2014

### Steven-Johnson's Syndrome/Toxic Epidermal Necrolysis

Lindsey Grant

Otterbein University, [lindsey.grant@otterbein.edu](mailto:lindsey.grant@otterbein.edu)

Follow this and additional works at: [https://digitalcommons.otterbein.edu/stu\\_msn](https://digitalcommons.otterbein.edu/stu_msn)

 Part of the [Immune System Diseases Commons](#), [Medical Pathology Commons](#), [Nursing Commons](#), and the [Skin and Connective Tissue Diseases Commons](#)

---

#### Recommended Citation

Grant, Lindsey, "Steven-Johnson's Syndrome/Toxic Epidermal Necrolysis" (2014). *Nursing Student Class Projects (Formerly MSN)*. 45.

[https://digitalcommons.otterbein.edu/stu\\_msn/45](https://digitalcommons.otterbein.edu/stu_msn/45)

This Project is brought to you for free and open access by the Student Research & Creative Work at Digital Commons @ Otterbein. It has been accepted for inclusion in Nursing Student Class Projects (Formerly MSN) by an authorized administrator of Digital Commons @ Otterbein. For more information, please contact [digitalcommons07@otterbein.edu](mailto:digitalcommons07@otterbein.edu).

# Steven-Johnson's Syndrome/Toxic Epidermal Necrolysis

Lindsey Grant RN, BSN, SRNA

Otterbein University, Westerville, Ohio

## Case Study

**Introduction:** Steven-Johnson's Syndrome (SJS) and Toxic Epidermal Necrolysis (TEN) are both diseases mediated by hypersensitive immune reactions resulting in "full thickness epidermal necrosis" characterized by skin detachment. However, in SJS, there is only 10% skin surface area involvement whereas in TEN, over 30% of the skin becomes detached. TENS has a 50% mortality rate. (East-Innis & Thompson, 2013, p. 590)

**Why Chosen:** SJS/TEN is a rare but extremely fatal disease. Initially, it is often mistaken as a simple allergic reaction to a new medication or environmental exposure because both cause truncal rashes and fevers. However, simple allergic reactions occur within days of exposure versus SJS/TEN, which will not mount signs and symptoms until one to three weeks after initial exposure; Meaning it is a delayed hypersensitivity reaction. (Cooper, 2012, p. 54)

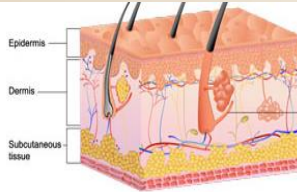
**Presentation of Case:**  
**Day 1:** Patient (pt) is a 56-year-old black female with a history of Chronic Obstructive Pulmonary Disorder (COPD), Diabetes Mellitus, Type II, and Hypertension presents to the hospital with Community-Acquired Pneumonia (CAP) versus Acute Exacerbation of COPD. Her vital signs are stable (VSSO). Her White Blood Cell (WBC) count 14,000x10<sup>9</sup>/L. The patient was placed on intravenous Vancomycin-Hcl for broad-spectrum coverage against suspected CAP.  
**Day 8:** Lesions and hemorrhagic crusting begin to form around her mouth. Anus appears swollen. VSS.  
**Day 9:** Truncal blister and papules begin to form over entire trunk, pt's pain in mouth, anus and trunk 6/10. Heart Rate (HR) 110 Sinus Rhythm, WBC18,000x10<sup>9</sup>/L, Respiratory Rate (RR) 24. Vancomycin discontinued due to suspected drug allergy.  
**Day 10, 05:00am:** Blisters have erupted over trunk and mouth, draining serosanguinous fluid, cultures sent, fissures emerging, HR 140 Atrial fibrillation with Rapid Ventricular Response, BP 96/40, RR 30, WBC24,000x10<sup>9</sup>/L. Pt intubated for Respiratory Failure, given 5L NS bolus, and started on Levophed at 15mcg/min.

## Pathophysiology

**Physiology of Skin:** The epidermis is the outermost layer of skin. Keratinocytes make up 90% of the cells found in the epidermis. They provide attachment the dermis and the epidermis.

**Underlying Pathophysiology:** Recent studies have revealed a link between certain Human Leukocyte Antigen (HLA) alleles found on keratinocytes and SJS/TEN. This demonstrates a genetic predisposition.

The metabolites of certain medications or environmental exposures are recognized by T-cell receptors (TCR) on T-lymphocytes as immunogenic which causes the TCR to bind with the immunogen, causing the release of a cascade of cytotoxic T-lymphocytes (CTL) and Natural Killer (NK) cells to lyse and destroy the keratinocyte. (Shih-Chi & Wen-Hung, 2014, p. 195)



Keratinocytes connect 90% of the epidermal cells to the dermis.

Once attached to the keratinocyte, Granulysin, a cytolytic protein released by CTLs and NK cells, works to destroy the keratinocyte by using its structure to cleave the mitochondria and lysosomes of the skin cell.

CTLs and NK also release perforin, another cytolytic protein, which forms pores in the cell wall of the skin cell to allow Granzyme B into the cell. Granzyme B induces DNA fragmentation by lysing the nucleus wall and dismantling keratinocyte DNA.

Additionally, Tumor-Necrosis Factor- $\alpha$  (TNF- $\alpha$ ), a cytokine that prompts cell apoptosis, has been found in the fluid collected from the...

Additionally, Tumor-Necrosis Factor- $\alpha$  (TNF- $\alpha$ ), a cytokine that prompts cell apoptosis, has been found in the fluid collected from the fluid draining from the fissures and bullae associated with SJS/TEN. TNF- $\alpha$  is a recruiter for additional WBC's to the area of inflammation, further exacerbating the immune response. TENS compromises over 30% of a patient's Body Surface area, so this hypersensitivity reaction can easily become a systemic inflammatory problem. (Shih-Chi & Wen-Hung, 2014, p. 202)

All this amounts to a severe sloughing of the epidermis from the dermis, resulting in partial to full thickness skin loss. Isotonic fluid loss, similar to that with burn victims is observed, along with excruciating pain.

However, keratinocytes and epidermal cells are not simply found in the skin. They make up parts of the eye, Gastro-Intestinal tract, all mucus membranes, the genitourinary system, and the trachea-bronchial tree. (Cooper, 2012, p. 54)

**Damage to these body parts result in:**  
**Eye:**

- Ocular discomfort, photophobia, conjunctivitis, inflammation of the lacrimal gland which is important for defense against microorganisms, infection, and permanent blindness. (Frizon et al., 2014, p. 56)

**GI Tract:**

- Mucositis (oral ulcerations), dysphagia, intestinal bleeding, and diarrhea which potentiates decreased absorption of nutrition necessary for healing.

**Lungs**

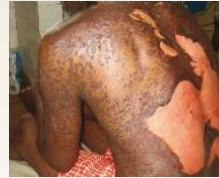- Increased permeability of the tracheobronchial leads to interstitial edema and infiltrates, inhibiting the diffusion of carbon dioxide and oxygen, leading to additional acid-base imbalance. Additionally, obstruction from shedding layers of epidermis from dermis in the airway can lead to obstruction and hypoxia. (Cooper, 2012, p. 55)

Therefore, it is theorized that a severe hypersensitive immune response occurs in which keratinocytes are marked for apoptosis due to a genetic predisposition coupled with exposure to drug metabolites that are interpreted as immunogenic.

**Case Continued:**  
**Day 10, 12:00pm:** 72 hours after oral lesions first presented, the patient's vital signs as follows:  
Temperature 101.8 degrees Fahrenheit  
HR 140, Atrial Fibrillation, RVR  
BP 80/30  
RR 35  
SpO2 92%  
Lactic Acid 3.0 mmol/L  
WBC 28,000x10<sup>9</sup>/L  
Diagnosis of TEN made.

The serosanguinous fluid loss through pt's fissures is so severe, she has now received 8L in NS boluses since appearance of first oral blister.  
Due to isotonic fluid loss, Levophed at 30mcg/min necessary to maintain a BP of 95/39. Neosynephrine drip started and BP rises to 101/60.

Pt is exhibited a marked decrease in urinary output, falling to less than 20mL/hour due to her extreme fluid loss.



Partial thickness sloughing of epidermis

Pt's kidneys experiencing damage as demonstrated by the Creatinine of 2.8 mg/dL due to lack of perfusion to their tissues and epidermal cell apoptosis affecting the genitourinary system. Pt's BUN 48 showing marked dehydration.

Upon Endotracheal suctioning, pink froth is emerging, suggestive of tracheobronchial damage. Pt's acid base balance indicates uncompensated metabolic acidosis although hypoxemia is also present with a PaO2 of 66mmHg. This is probably due to her increased interstitial edema and atelectasis caused by increased capillary permeability and weakness. Pt's Positive End Expiratory pressure increased to 10. Pt paralyzed and sedated to increase ventilator compliance.

Pt now exhibited signs of GI bleeding with small amount of bright red blood emerging from anus. Scope not ordered at this time due to notion that it would cause further GI bleeding.

## Case Resolution

Amiodarone IV started for A. Fib RVR. At this time the health care team cannot start Heparin because of suspected GI bleed.

Pt now has over 50% epidermal loss due to sloughing mostly over trunk, neck and face. Orders received to leave all adherent materials (patches, dressings) in place until further notice due to fear for more loss. Pt placed on air-fluidized bed and not to be turned.

**Resolution:** Partially as a result of not being able to be turned, pt developed severe chronic PNA and required a tracheotomy.

The emergence of new blisters stopped around Day 15, but the hypersensitive sloughing nature of the skin did not stop until about Day 40. Despite having an air-fluidized bed made for burn victims designed to decrease bony prominence pressure, pt developed a sacral deep pressure ulcer, stage III that became infected.

Pt could not be on prophylactic Heparin due to compromised skin tissue and internal GI bleeds from necrosis of epithelial GI tissue. Subsequently, pt suffered a severe ischemic stroke in her Middle Cerebral Artery on day 28 of hospital admission due to an embolized clot from her A. Fib. Pt lost use of both legs, had increased weakness in her arms and expressive aphasia. She remained bedbound indefinitely.

After two months of hydrogel dressings to over 40% of the pt's Body Surface Area, new areas of necrosis stopped forming. Pt's survived for one full year past her diagnosis, and her remaining few months included immobility complications such as UTI's, bedsores, depression, and anxiety. Eventually, pt was made DNR-CC. Pt's VS remained approximately as follows HR 80's, BP 70/30, RR 35. She eventually passed due to left ventricular heart failure.

## Implications for Nursing Care

Nurses lie on the forefront of patient assessment. For diseases such as SJS/TEN, early identification of emerging signs and symptoms can save lives. Nurses must be especially vigilant about assessing a patient's trunk and mouth, which are often zones neglected in non-critical care patients for concealment and privacy reasons. If a Nurse is charting "skin intact," he or she has a responsibility to know the condition of the patient's integumentary system. (Cooper, 2012, p. 52)

Nurses also are heavily relied on to know all the medications prescribed, over-the-counter and herbal remedies a patient is taking. This is crucial for identifying a cause for SJS/TEN. There are between 100-200 drugs that possibly cause SJS/TEN. Also crucial is once identifying a causative agent, immediately discontinuing that medication. (Cooper, 2012, p. 53)

The most important factor in SJS/TEN treatment is time. The health care team needs to identify and remove the offending medication or environmental exposure quickly to limit damage to the body. SJS/TEN is often mistaken for a simple allergic reaction due to the rash commonality. However there are crucial and life-altering differences. Chiefly, the rash in SJS/TEN is painful and blisters, and respiratory symptoms are a late indication of disease in SJS/TEN where as in allergic reaction, respiratory reactions are early. (Cooper, 2012, p. 54)

## Diagnosis

Firstly, the health care team must rule out an infectious cause for the symptoms. "Patients should be tested with serology tests (IgM and IgG) and PCR (to assess viral replication) for herpes simplex virus 1 and 2, varicella-zoster virus, cytomegalovirus, Epstein-Barr virus, human herpes virus 6 and 7, parvovirus and *M pneumoniae*." (Ferrandiz-Pulido & Garcia-Patos, 2013, p. 1001) Acute inflammatory mediators such as fibrinogen and CRP must be monitored. (Dedric et al., 2012, p. 58)

Additionally, "the severe sloughing of the epidermis will produce a positive Nikolsky's sign; a diagnostic maneuver of applying lateral pressure of the surface of the epidermis and sloughing of the skin occurs." However, "A definitive diagnosis is made by full-thickness epidermal necrosis on biopsy." (Barrick & Macatuno, 2014, p. 1104)

## Causes

The main culprits of medication causes for SJS/TEN come from NSAIDs, anti-epileptics and antibiotics. (Pakran et al., 2013, p. 86)

- Vancomycin-Hcl
- Valproate
- Allopurinol
- Ibuprofen

## Risk Factors

- Male
- Age 20-30
- Previously diagnosed malignant neoplasms, AIDS, lupus, and viral infections. (Knight et al., 2014, p. 2)
- Genetic predisposition to skin reactions to specific medications. (Karkucak, et al., 2012, p. 301)

## Treatment

Remove offending medication immediately. Supportive care might include air-fluidized beds to prevent deep tissue injury, hydrogel dressings to minimize epidermal damage, ventilatory support, nutritional support to optimize wound healing, IV fluid replacement and plasmapheresis to hasten the removal of the offending medication from the body. Immunosuppressive drugs such as corticosteroids are now under investigation to determine validity. (Cooper, 2012, p. 55)

In conclusion, SJS/TEN is a severely debilitating, potentially fatal hypersensitivity reaction that requires vigilant supervision and delicate treatment. If caught early, chances of survival markedly improve, however it is so rare, it is often mistaken for an allergic reaction. Advances in supportive care and immunosuppression may prove helpful in the future treatments of SJS/TEN.

### References

Barrick, C., & Macatuno, E. (2014). Progressive Rash, Oral Lesions, and History of Antibiotic Use in a 17-Year-Old Boy: Stevens-Johnson Syndrome: A Case Report. *Clinical Pediatrics*, 53(11), 1101.

Cooper, K. L. (2012). *Skin and Wound Care. Drug Reaction, Skin Care, Skin Loss. Critical Care Nurse*, 32(4), 52-59.

Dečić, A., Kantardžić, A., Hodžić, M., Bešliagić, E., & Avdić, M. (2012). STEVENS - JOHNSON SYNDROME FROM DIAGNOSIS TO THERAPY - multidisciplinary approach. *Medical Journal*, 18(1), 55-59.

East-Innis, A. D., & Thompson, D. S. (2013). Stevens-Johnson Syndrome and Toxic Epidermal Necrolysis at the University Hospital of the West Indies, Jamaica. *West Indian Medical Journal*, 62(7), 589-592.

Ferrandiz-Pulido, C., & Garcia-Patos, V. (2013). A review of causes of Stevens-Johnson syndrome and toxic epidermal necrolysis in children. *Archives Of Disease In Childhood*, 98(12), 998-1003.

Frizon, L., Araujo, M., Andrade, L., Yu, M., Wakamatsu, T., Hoffling-Lima, A., & Gomes, J. (2014). Evaluation of conjunctival bacterial flora in patients with Stevens-Johnson Syndrome. *Clinics*, 22(7), 56.

Karkucak, M., Bülbül, E., Turan, H., Yakut, T., Toka, S., & Sarcaoglu, H. (2012). Investigation of Monomeric-Binding Lectin gene Polymorphism in Patients with Erythema Multiforme, Stevens-Johnson Syndrome and Stevens-Johnson Syndrome/Toxic Epidermal Necrolysis Overlap Syndrome. *Balkan Medical Journal*, 29(3), 301-303.

Knight, L., Muloiva, R., Dlamini, S., & Lehloanya, R. J. (2014). Factors Associated with Increased Mortality in a Predominantly HIV-Infected Population with Stevens-Johnson Syndrome and Toxic Epidermal Necrolysis. *Plos ONE*, 9(4), 1-5.

Pakran, J., Pavithran, K. K., Kuruvilla, S., & Anand, M. (2013). Coexistence of Stevens-Johnson syndrome and hemophagocytic syndrome. *Indian Journal Of Paediatric Dermatology*, 14(3), 83-87.

Shih-Chi, S., & Wen-Hung, C. (2014). Cytotoxic Proteins and Therapeutic Targets in Severe Cutaneous Adverse Reactions. *Toxins*, 6(1), 194-210.

Yang, L. P., Zhang, A. L., Wang, D. D., Ke, H. X., Cheng, Q. Q., & Wang, C. C. (2014). Stevens-Johnson syndrome induced by the cross-reactivity between telocaplanin and vancomycin. *Journal Of Clinical Pharmacy & Therapeutics*, 39(4), 442-445.



OTTERBEIN UNIVERSITY